

# Benefits of a Corneo scleral vs a scleral design in a case of conjunctival prolapse

Patricia Flores-Rodríguez DOO, MSc, PhD; Hugo Legaria Contact lens technician. Centro Voss. Argentina.

## Background

Scleral contact lens-induced conjunctival prolapse is a condition that occurs in a significant percentage of scleral lens wearers. Conjunctival prolapse is also referred to as conjunctival chalasis or hooding, and it represents an entrapment of the loosely elastic conjunctiva near the limbal region under a scleral contact lens. A recent study by Pat Caroline showed that Prolapse occurs in 20-30% of scleral lens wearers presenting a wide range of corneal conditions. It occurs most frequently at the inferior corneal-scleral junction. The suggested pathogenesis of conjunctival prolapse is related to induced pressure forces that can pull the conjunctiva under the lens. These forces are greater with greater vault over the limbal area and may be related to the inferior scleral lens positioning. If this complication become prolonged and continuous, it could produce neovascularization in the affected zone.

## References

1. Walker, M., P. Caroline, M. Lampa, B. Kinoshita, M. Andre, and R. Kojima. 2014. A proposed mechanism for scleral lens induced conjunctival prolapse. Poster Presentation Global Specialty Lens Symposium, Las Vegas, Nevada, USA.
2. Caroline, P. 2012. Conjunctival prolapse, hooding, chalasis or... Contact Lens Spectrum 27:56.
3. Jedlicka, J. 2012. Solving Scleral Lens Complications. Contact Lens Spectrum 27:40-44.

## Disclaimer

Patricia Flores-Rodríguez is partial employee of Menicon Co., Ltd.

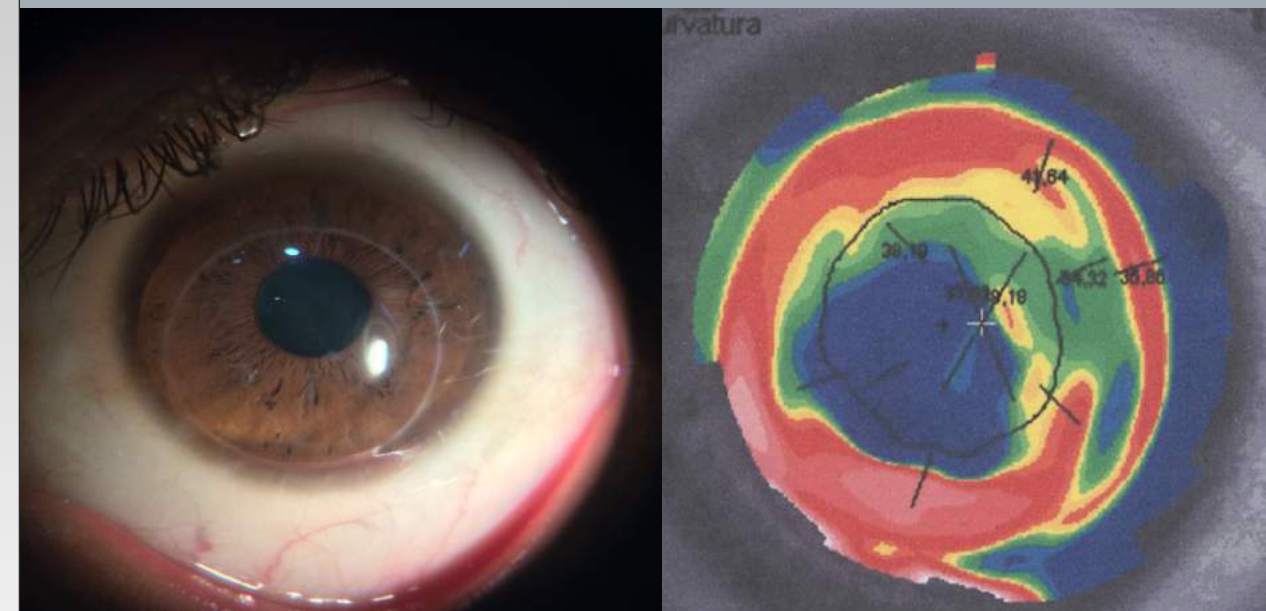
## Pertinent Findings

### I. Ocular history

- General information: 30-year old Caucasian male.
- Ocular medical history: Post Penetrating Keratoplasty 5 years ago.
- Chief complaint: suboptimal vision.
- Other salient information: He has never worn contact lenses and was referred by the Ophthalmologist to explore the possibility of wearing scleral contact lens for comfort and improved visual acuity .

### II. Exams:

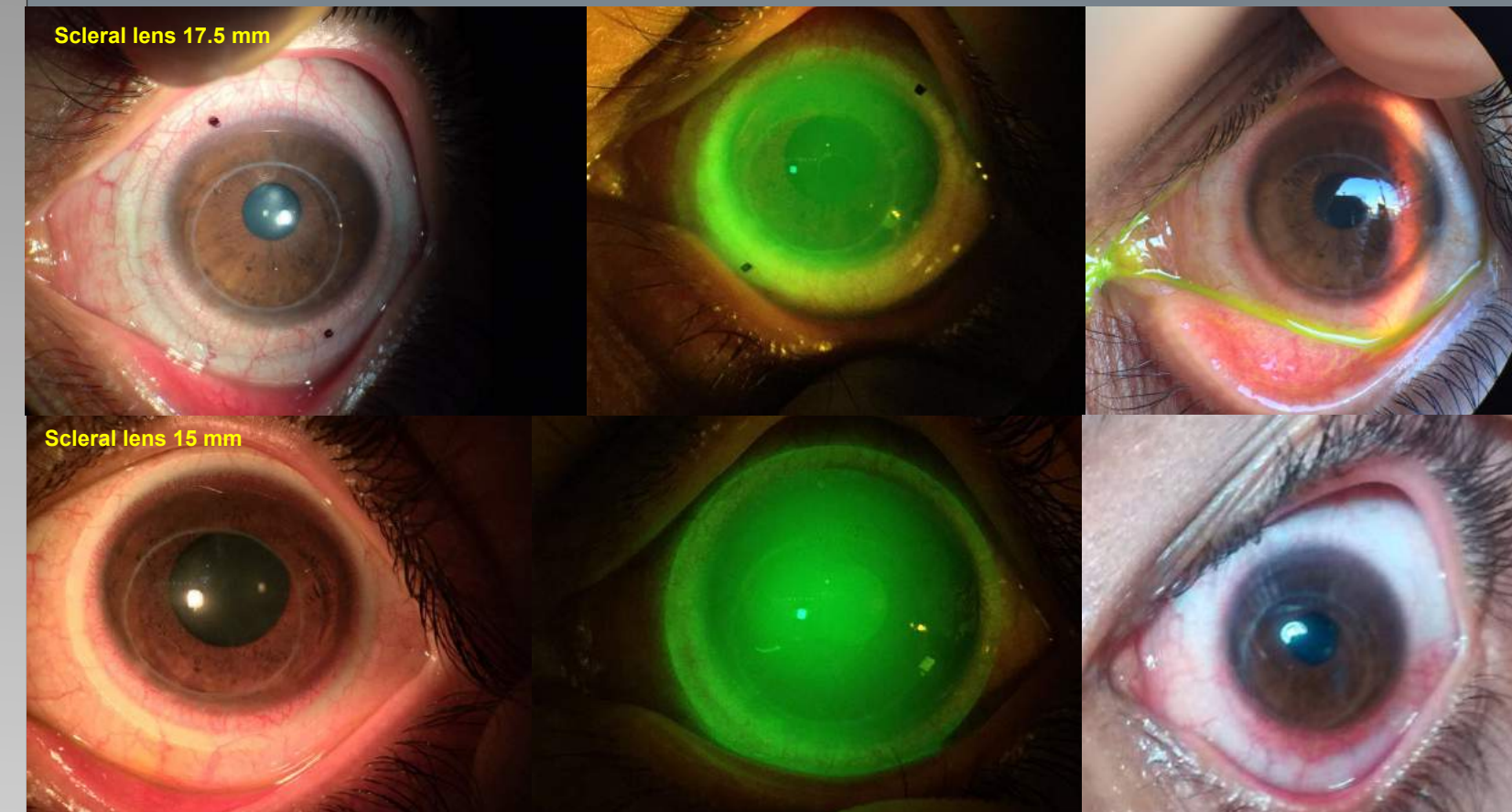
- Visual Acuity: Without contact lenses: 20/200; Subjective refraction: 20/100; Stenopeic hole (pinhole): 20/30
- Slit Lamp and Corneal Topography: Corneal transplant offset to the lower quadrant Transparent refractive means – see picture



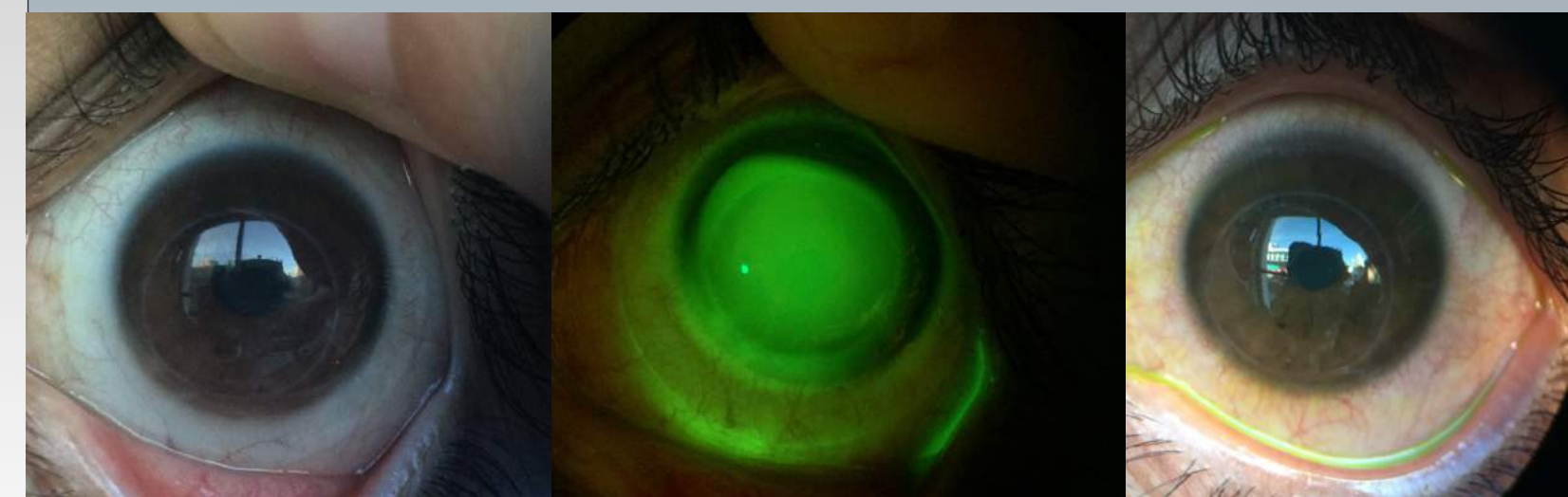
## Contact lens fitting

Lens designs trialled . Atlantis scleral lens – X cel (17 and 15 mm) and corneo – scleral Rose K2 XL –( Menicon 16 mm). All lenses were fitted according to the manufacturers instructions.

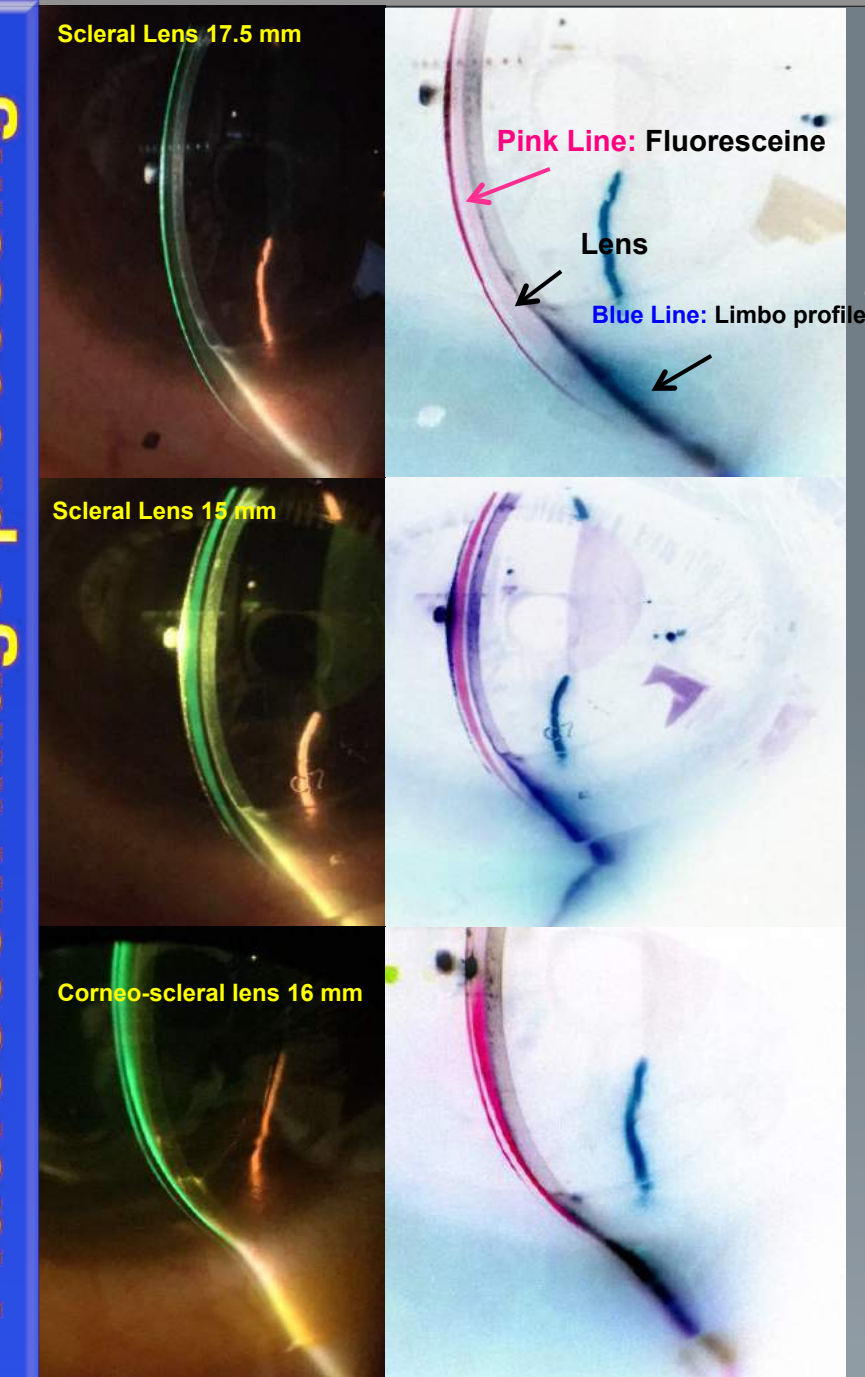
**Scleral design (diameter 17 mm and 15 mm):** In this clinic case 15 and in 17.5 mm diameter scleral lenses have a reduced scleral support band, which makes the vault diameter large for this cornea and causes lens decentration, increasing inferior and limbal clearance, and consequent conjunctival prolapse and hyperemia. Conjunctival blanching and conjunctival injection are evident after 8 hours use with this design.- see diagram



**Rose K2 XL Corneo-scleral design (diameter 16 mm):** This design has its landing zone on the cornea, uses minimum clearance over the limbus and has an open edge design. This significantly reduces pressure force at the limbus making it virtually impossible to produce conjunctival prolapse.



## Fluorescein image processing



Fluorescein image processing help to improve visualization different area lenses. The **pink line** represent fluorescein (clearance). The **Blue line** represent limbal profile.

We can observed increased vault over the limbal area in scleral design, this produced a pressure force and increased conjunctival prolapse.

Decreasing the limbal clearance by using the Rose K2 corneo scleral design reduces the possibility of conjunctival prolapse development

## Conclusions

Corneo-scleral designs like that of Rose K2XL which land on the cornea inside the limbus, have a significantly smaller corneal vault than scleral lenses which vault over the cornea and land completely on the conjunctiva/sclera. These designs can help to center the lens , reduce lower limbal clearance and subsequent forces over the limbal area. These designs are an excellent option to prevent conjunctival prolapse produced by pressure forces in scleral lens designs.